

POD3PMD Neurology: Introduction

Jeff Carnett, D.P.M.

Resources

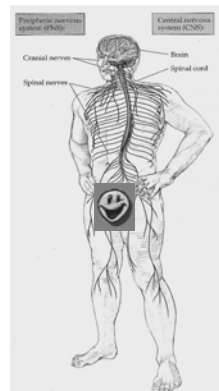
- Neurological assessment form - copy in clinic, and can download from WebCT
- **Lecture notes**
- **WebCT online course**
 - Update course in Neurological Ax
 - Use your student login/password
- **Neurology manual** (green, in bookshop)
 - You will be asked to read particular articles later this semester (questions on a worksheet)

Anatomy Review

- Nervous System:
Not fully understood

Major Divisions

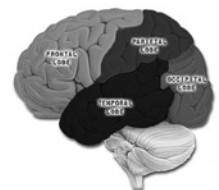
- Central Nervous System
Composed of Brain and Spinal Cord (parts encased in bone)
 - Peripheral Nervous System
Composed of Cranial and Peripheral nerves (not in bone). 2 subdivisions:
 - Afferent Nerves (sensory/to cns)
 - Efferent Nerves (motor/away from cns)
- Somatic Nerves (Voluntary), CNS to skeletal ms
Autonomic Nerves (Involuntary), CNS to heart, organs, glands.
further subdivided into 1) Sympathetic
2) Parasympathetic



The Brain

- Cerebral Hemispheres
 - + Two large bodies resting on the brain stem.
 - + Joined by a mass of myelinated fibers: Corpus Callosum

- 2 Hemispheres
 - 4 major divisions:
 - 1) Frontal Lobe
 - 2) Temporal Lobe
 - 3) Parietal Lobe
 - 4) Occipital Lobe



Frontal Lobe

- Origin of voluntary motor control
- Control conjugate eye movement
- Lesions result in "Upper motor neuron signs"
i.e.. Paralysis, spasticity, increased DTRs, +Babinski sign

Temporal Lobe

- Language
- Limbic system-not understood
- Lesions: psychic s/s, hallucinations.

Parietal Lobe

- Voluntary motor function
- Integration, correlation, interpretation of sensory input
- Lesions can cause:
 - *Alexia-inability to comprehend written word
 - *Agraphia-inability to write
 - *Agnosias: can't recognise
 - *Confusion of right from left
 - *Acalculia-inability to calculate
 - *Spatial disorientation
 - *Apraxia: can't carry out a purposeful sequence of motor actions.

Occipital Lobe

- Vision
- Lesions/irritation results in hallucinations, flashing lights, blind spots. These are common in people with migraines, strokes, tumours or trauma of this area.

Cerebellum

- Hind brain.
 - Processes info from cerebral motor cortex.
- Mainly balance, posture, smooth movements

Peripheral Nervous System

- Composed of nv fibres-long axon and dendrite
- Types of fibres:
- 1) Nonmyelinated-ANS
slow
 - 2) Myelinated fibres-faster

Spinal Nerves

- 31 pairs
- Each connected to spinal cord by 2 roots (ant & post)

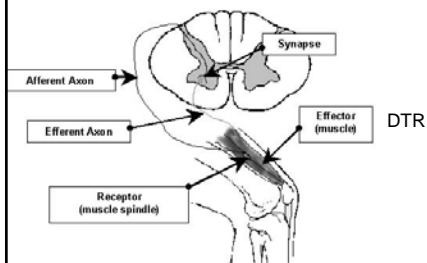
Cranial Nerves

- 12 pairs, exiting skull through foramina

Nerve-	function-	examination
I: OLFACTORY-	SMELL	TEST ODOUR
II: OPTIC-	VISION	VISUAL ACUITY
III: OCULOMOTOR-	PUPIL AND EYE MOVEMENT	CONFRONTATION & EXTINCTION OF VISION
IV: TROCHLEAR-	MOVEMENT OF EYE	DROOPING?
V: TRIGEMINAL-	FACE SENSATION, MUSCLE	PAIN, TOUCH OF 3 BRANCHES/CORNEAL
VI: ABDUCENS-	MOVEMENT OF EYE	PUPIL SIZE WITH LIGHT
VII: FACIAL-	TASTE, SALIVASTION, TEARING, EXPRESSION	EXPRESSIONS
VIII: ACOUSTIC-	BALANCE, HEARING	HEARING
IX: GLOSSO-PHARYNGEAL-	SWALLOWING	SOUR/BITTER, GAG
X: VAGAL-	AUTONOMIC, TASTE, SWALLOWING	UVULA SYMMETRY SWALLOWING
XI: ACCESSORY-	MOVEMENT OF NECK AND SHOULDER MUSCLES	
XII: HYPOGLOSSAL-	TONGUE MOVEMENT	SHOULDER SHRUG TONGUE SYMMETRY, MOTIOR (LTDN)

Reflexes

- INVOLUNTARY REACTION TO STIMULATION



ANS: REVIEW

- Parasympathetic: bradycardia, hypotension, bronchoconstriction, myosis, vasodilation. Increased peristalsis, erection
- Sympathetic: tachycardia, hypertension, bronchodilation, vasoconstriction, decreases peristalsis, ejaculation

Do: Worksheet for next time